

Imaging Guidelines Resource for AHOD1331

**CHILDREN'S
ONCOLOGY
GROUP**

The world's childhood
cancer experts

Response

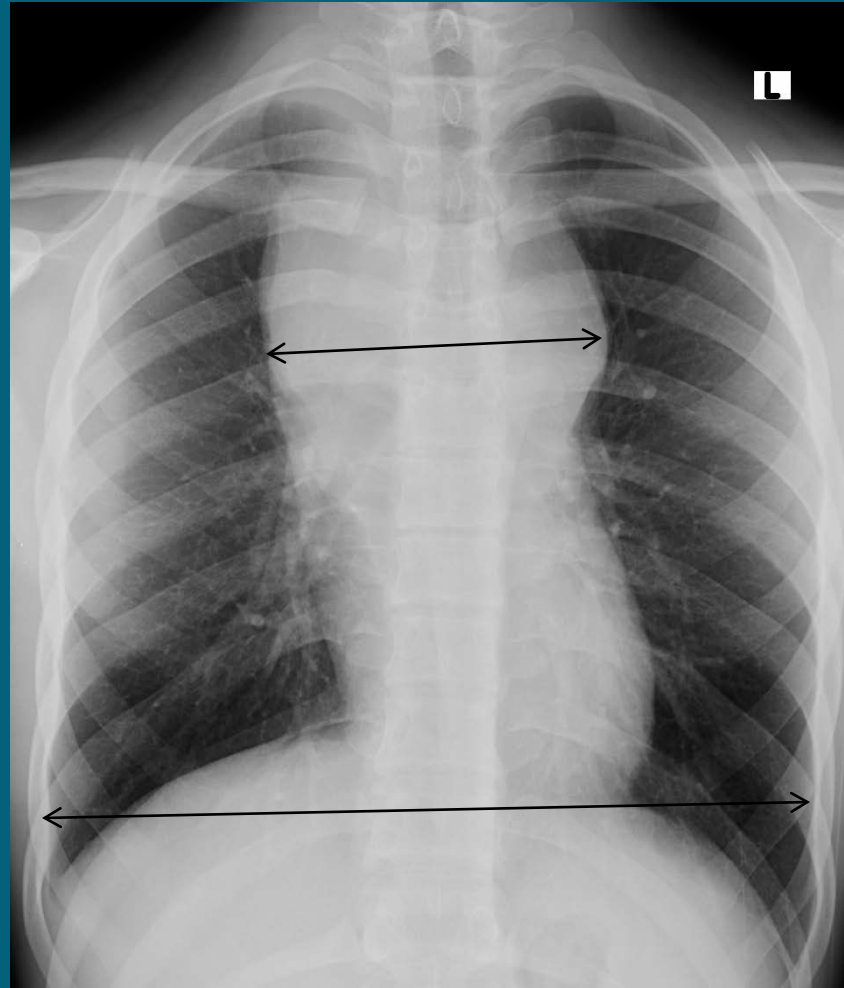
- Response in AHOD1331 will be based only on FDG-PET and not decrease in size of lesions
- The only size determinations of concern to the primary institution is measurement of bulk disease at baseline and measurement to assess for progressive disease

Measurement of Bulk Disease

- Maximum transverse diameter of mediastinum on PA upright chest radiograph $>1/3$ the diameter of the thorax at the level of the diaphragm
- Maximum diameter of non-mediastinal nodal mass = or > 6 cm. in axial or craniocaudal plane. **This is new from prior protocols**

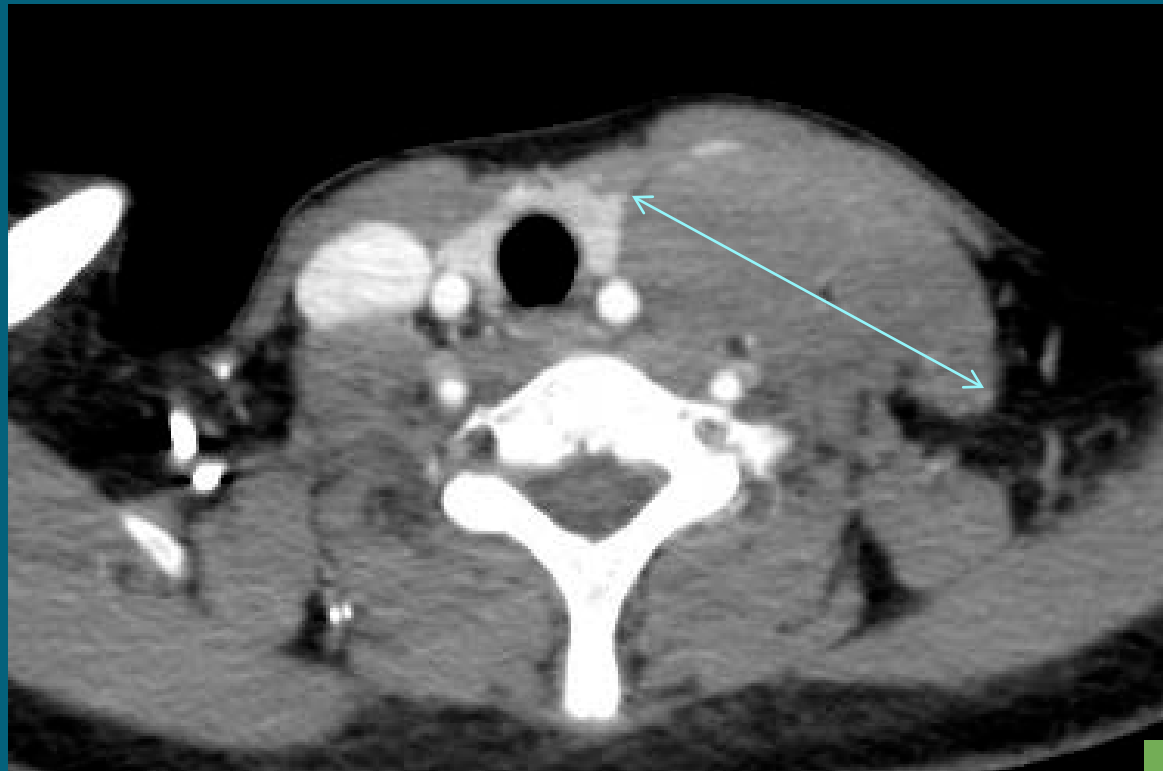Mediastinal Bulk

Mass $>$ $\frac{1}{3}$ diameter of thorax at level of diaphragm



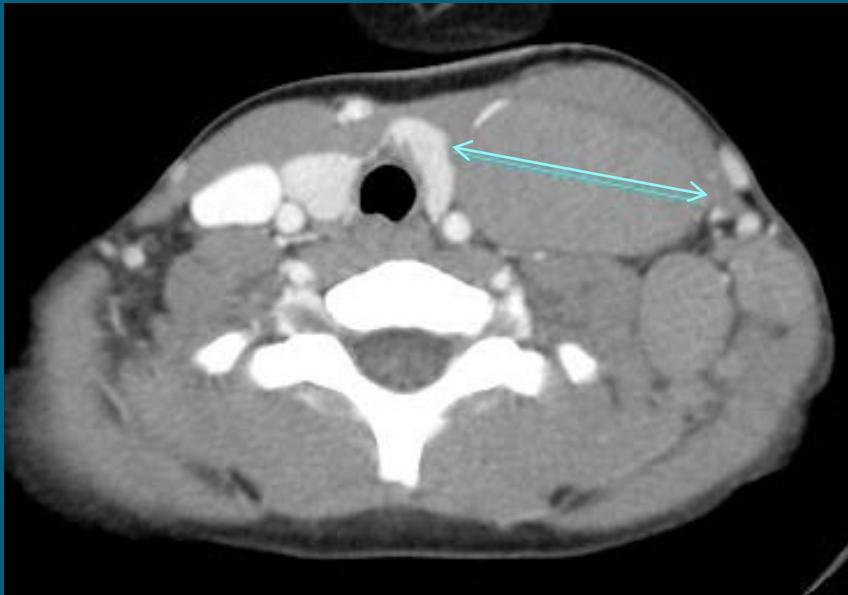**CHILDREN'S
ONCOLOGY
GROUP**

Non-mediastinal nodal bulk > 6cm.

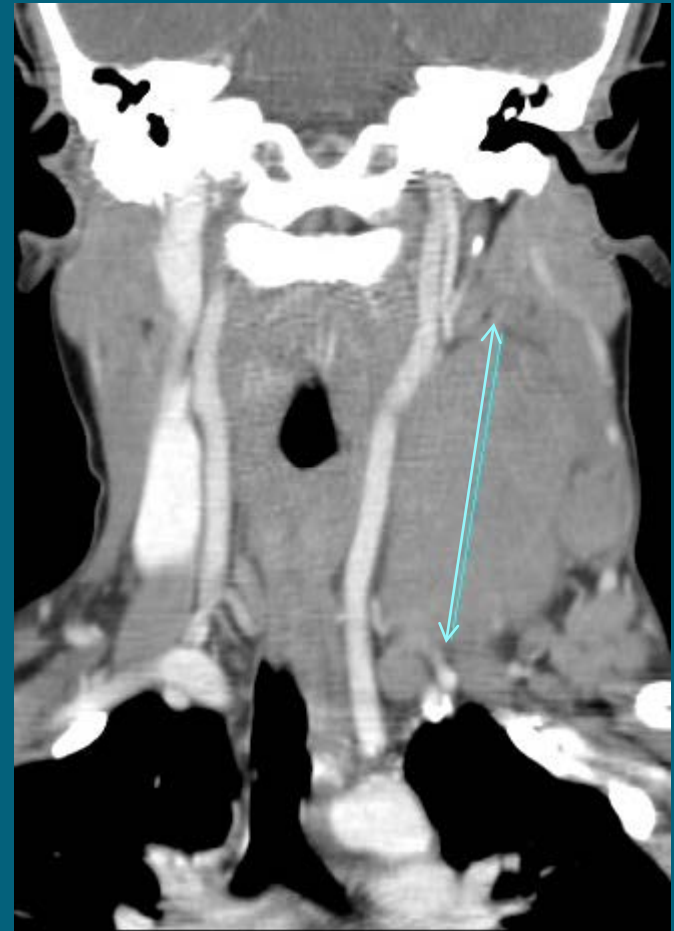

**CHILDREN'S
ONCOLOGY
GROUP**

Non-mediastinal bulk not > 6 cm. in axial plane but > 6 cm. cranio-caudally

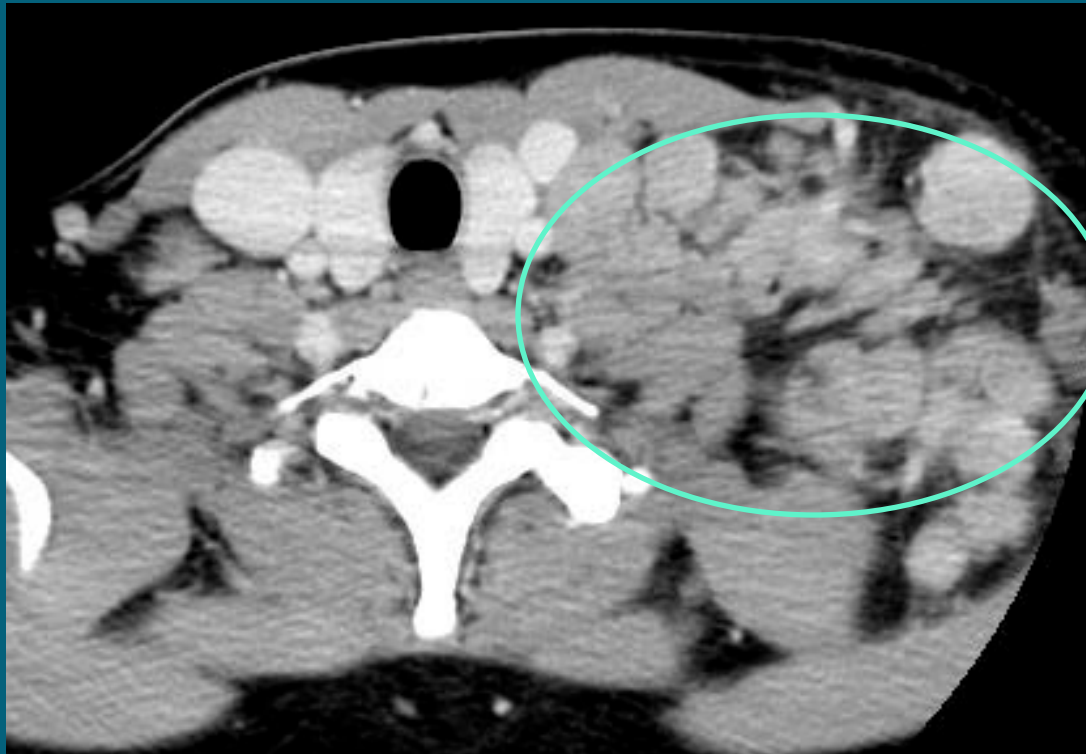

Axial 4.8 cm.



Cranial-caudal 7.0 cm.

Cluster many small nodes =
NOT BULK



**CHILDREN'S
ONCOLOGY
GROUP**

Deauville Criteria –
System of FDG-PET response based
on 5 levels of decrease in avidity;
found to be of good prognostic
accuracy in adult trials

Deauville Criteria

- 1. No uptake above surrounding background
- 2. $<$ or $=$ mediastinal blood pool
- 3. $>$ mediastinal blood pool but $<$ or $=$ liver
- 4. Moderate increase compared to liver
- 5. Marked increase compared to liver

Interim **post Cycle 2** PET Response

- FDG-PET positive is defined as Deauville scores 4 or 5 (**SRL**)
- FDG-PET negative is defined as Deauville scores 1, 2, or 3 (**RRL**)

SRL – Slowly Responding Lesion
RRL – Rapidly Responding Lesion

**CHILDREN'S
ONCOLOGY
GROUP**

End chemotherapy PET(PET 5) Response

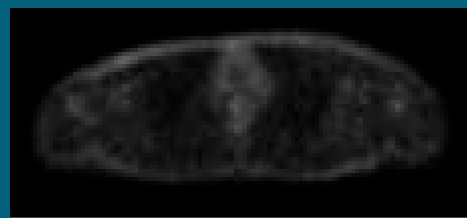
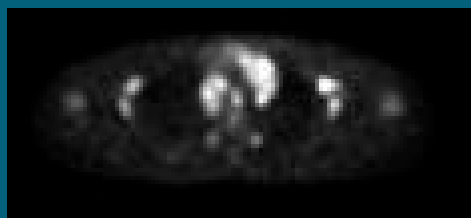
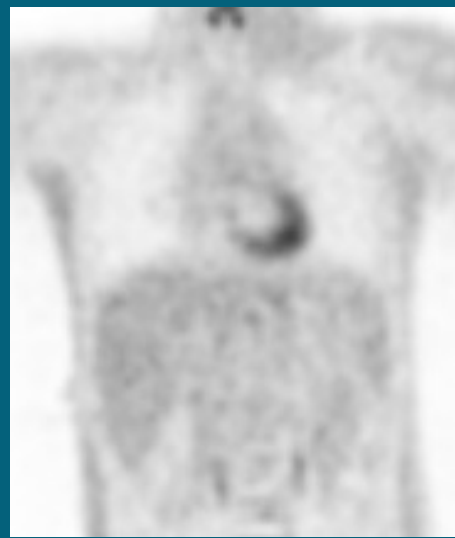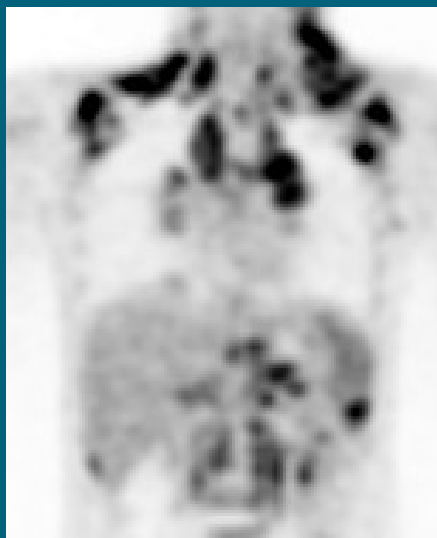
- FDG-PET positive is defined as Deauville scores 3, 4, or 5 (**IMR**)
- FDG-PET negative is defined as Deauville scores 1 or 2 (**CMR**)

IMR – Incomplete Metabolic Response

CMR – Complete Metabolic Response

**CHILDREN'S
ONCOLOGY
GROUP**

All PET avid areas now < liver

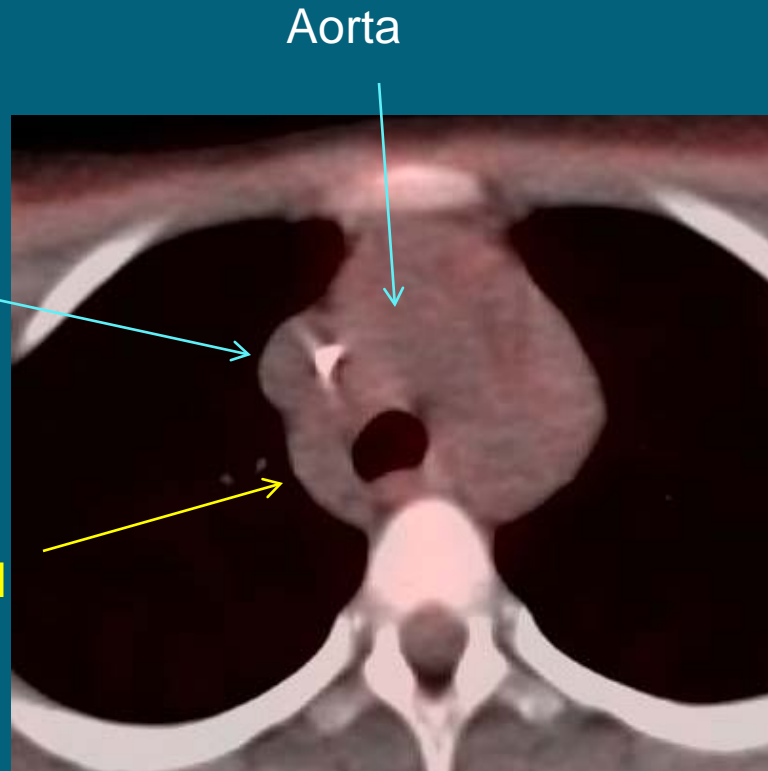


Pre-study

Post chemotherapy

**CHILDREN'S
ONCOLOGY
GROUP**

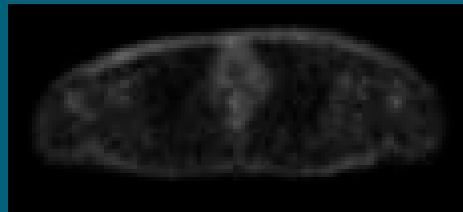
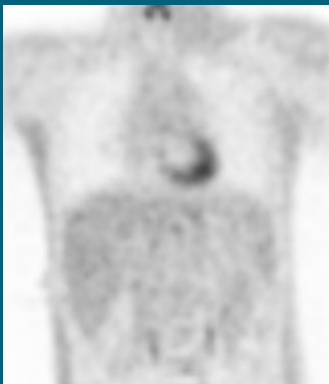One node at or < Blood Pool



SVC

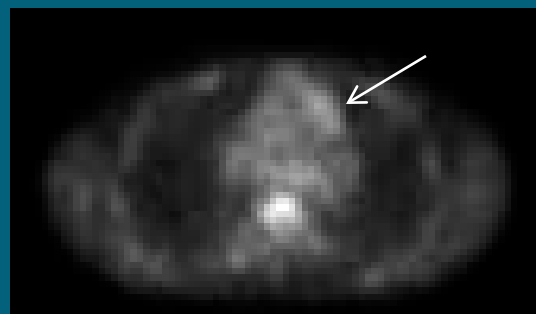

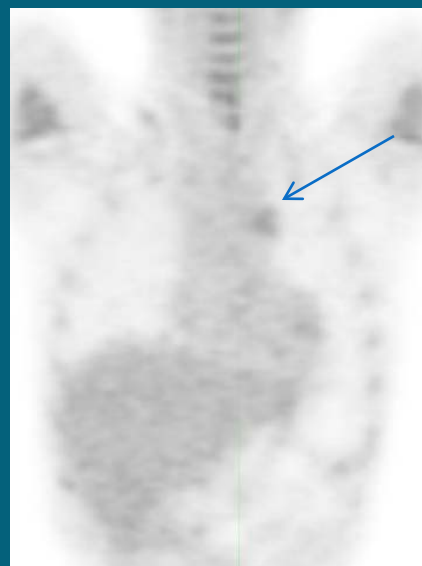
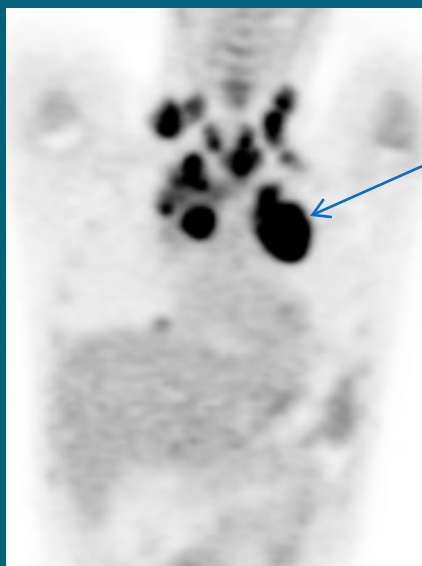
Aorta

Right paratracheal mass < or = blood pool



**CHILDREN'S
ONCOLOGY
GROUP**

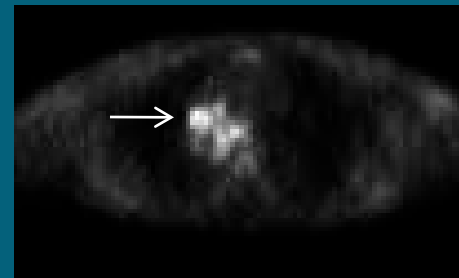
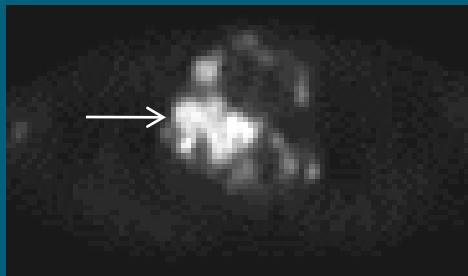
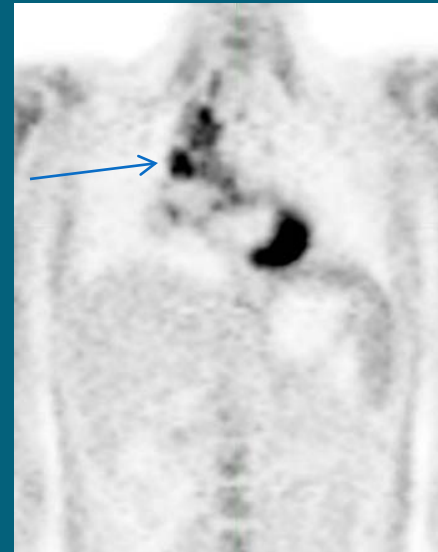
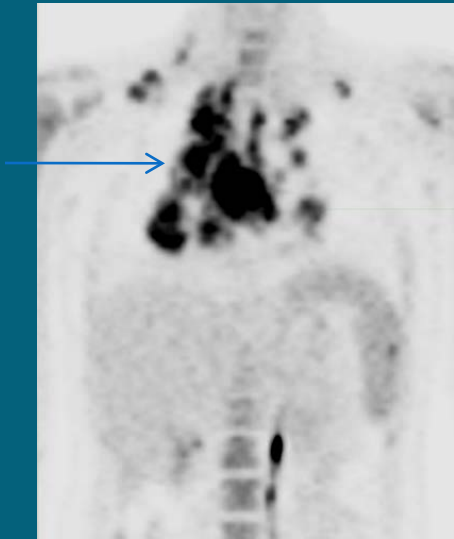
Mediastinum = Liver post therapy



Pre-study

Post therapy

Mediastinum > liver post therapy



Pre-study

Post therapy

**CHILDREN'S
ONCOLOGY
GROUP**

Spleen – Complete Response

Prior Protocols

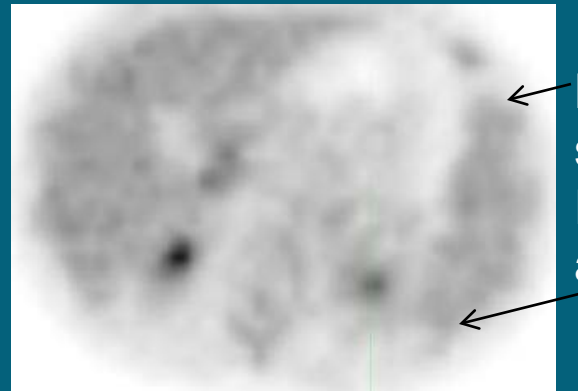
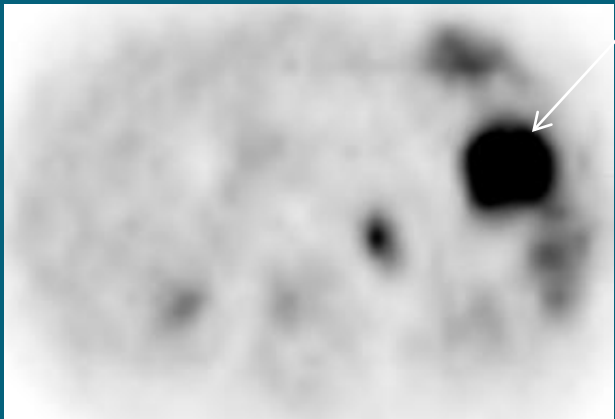
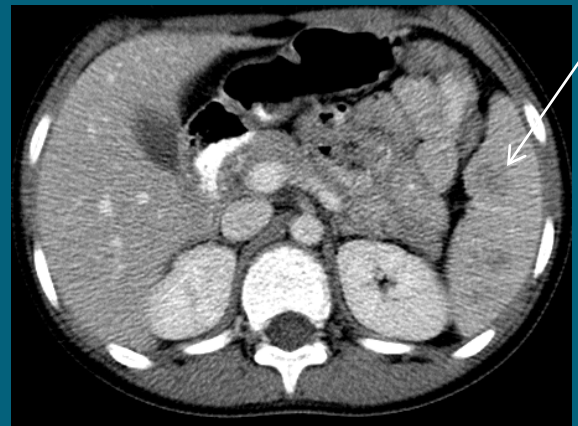
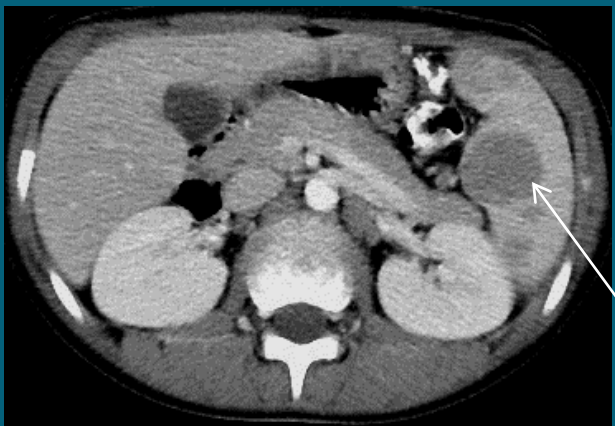
- No residual contrast CT abnormality
- No residual PET avidity

AHOD1331

- Residual contrast CT abnormality decreased by >50% or is <1cm. in diameter
- No residual PET avidity

Spleen

Residual CT



Pre-Study

Post therapy Negative