

Image Fusion Benchmark

This benchmark case and questionnaire have been accepted by the Quality Assurance Subcommittee of the Radiation Therapy Committee of COG. Institutions treating patients on COG protocols which require the fusion of different CT and/or MR imaging studies must satisfactorily complete this case and the accompanying questionnaire. The benchmark is not disease site specific and applies to all protocols requiring CT and MR image fusion.

BENCHMARK:

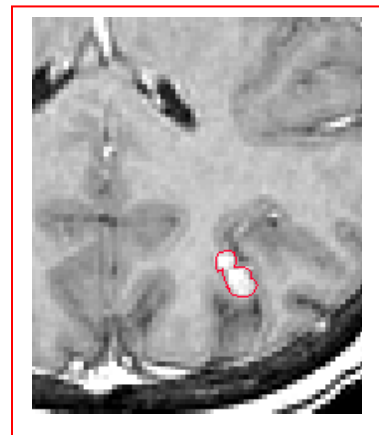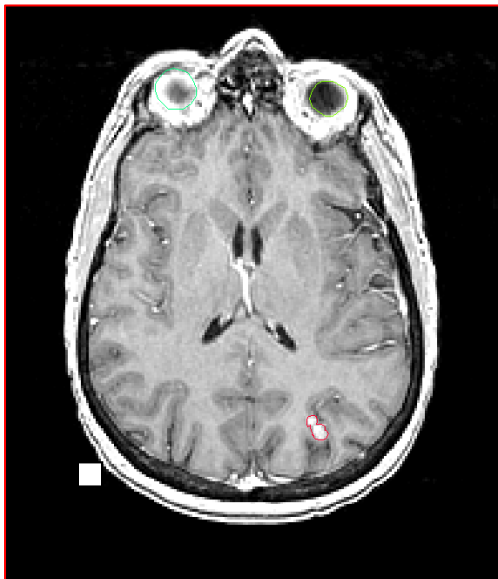The benchmark case consists of two DICOM image sets which must be fused. The contrast enhancing lesion in the left occipital lobe on the MR images shall be contoured. The accuracy of the fusion will be assessed from the location of the lesion on the CT images.

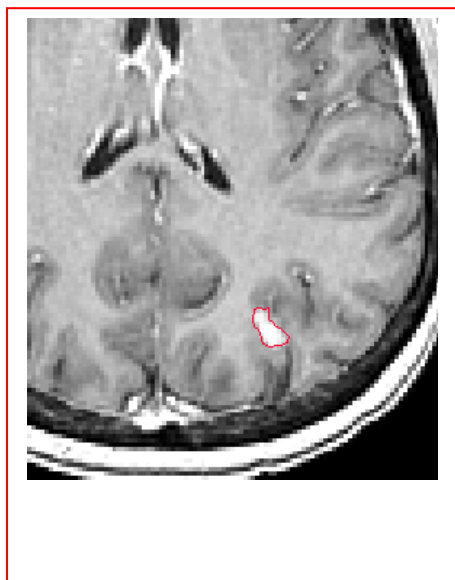
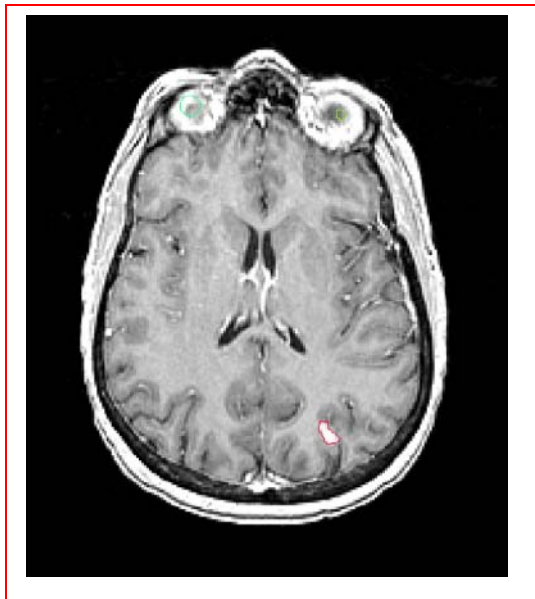Specifics:

Two DICOM imaging sets, one CT and one MR, for patient “QARC Fusion”, are supplied. The CT imaging set consists of 62 images. The axial MR imaging study consists of 83 images. These are the two sets which shall be fused using your usual technique. If your planning system allows several techniques, you should use whichever gives you the greatest confidence in this case.

The image sets may be downloaded from the QARC website (www.QARC.org) as two zip files, one for the MR and one for CT. Call QARC at 401-753-7600 for the required password.

On the MR scan, there is a small enhancing lesion in the posterior occipital lobe. The lesion shall be outlined on axial slices 44 and 45 ($z = 5.2$ mm and 7.2 mm) as illustrated below.





Material to be submitted:

This benchmark should be submitted digitally if your planning system has the capability of exporting the DICOM RT spatial registration file, which contains the spatial transformation for the MR image set. Submission requirements are listed below for both digital and non-digital submissions. If you are not able to export the spatial registration file as a DICOM file, follow the instructions for non-digital submissions.

Digital Submissions

Submit the following items. Instructions for submission of digital data can be found at www.QARC.org under "Digital Data → RT Treatment Planning."

- 1.) CT image set (DICOM) as exported from your planning system.
- 2.) MR image set (DICOM) as exported from your planning system.
- 3.) DICOM RT Structure file.
- 4.) Spatial Registration file (DICOM).

Submit the following additional materials as hardcopy or as screen capture files (jpegs, bmps, etc.).

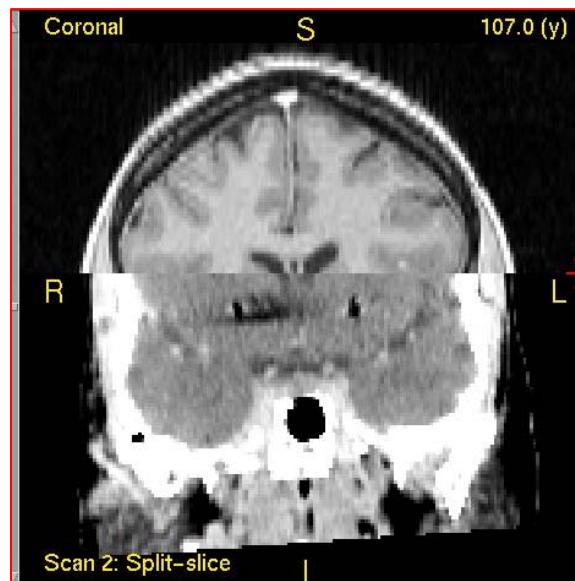
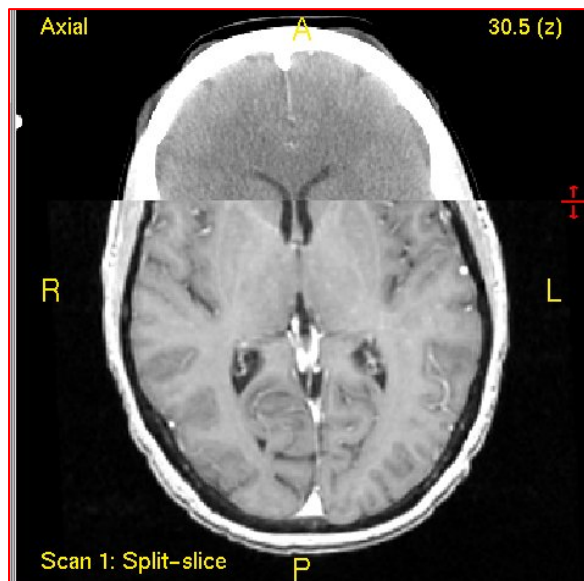
- 5.) The report from the planning system of the results of the fusion, if available, i.e. whatever statistics or distances-to-agreement is generated by your planning system for the success of the fusion.
- 6.) The x, y, z coordinates of two points in the CT coordinate system:
 - a. The center of the target volume
 - b. The center of the first rod (of the stereotactic localization ring) on the most inferior CT slice. The first rod is the one on the left (patient's right) with the largest diameter. (See illustration below.)

- 7.) A completed Image Fusion Questionnaire (included with this benchmark on page 5).

Non-Digital Submissions

Submit the following as hardcopy or as screen capture files (jpegs, bmps, etc.).

- 1.) Split axial images, showing part CT image and part MR image, or overlaid images, depending on the capabilities of your system, at the level of the ventricles.
- 2.) Coronal split or overlaid images through the ventricles.
- 3.) Sagittal split or overlaid images through the left and right eye.
- 4.) Axial, sagittal and coronal images of the CT scan through the center of the target volume and any additional axial slices on which the target volume appears. The outline of the target volume shall be superimposed. There must be an indication of the scale of the images.
- 5.) The report from the planning system of the results of the fusion, if available, i.e. whatever statistics or distances-to-agreement is generated by your planning system for the success of the fusion.
- 6.) The x, y, z coordinates of two points in the CT coordinate system:
 - c. The center of the target volume
 - d. The center of the first rod (of the stereotactic localization ring) on the most inferior CT slice. The first rod is the one on the left (patient's right) with the largest diameter. (See illustration below.)
- 7.) A completed Image Fusion Questionnaire (included with this benchmark on page 5).



Examples of split images illustrating fusion: (These are intentionally not at the levels of the lesion.)

x, y, z coordinates of the center of the target and the center of this rod on the most inferior CT slice are to be submitted.

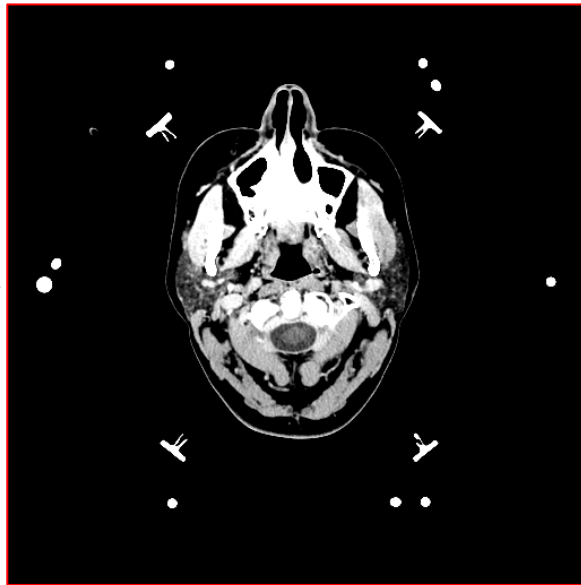


Image Fusion Questionnaire

Institution: _____

Address: _____

Person Completing This Benchmark: _____

_____ Radiation Oncologist _____ Physicist _____ Dosimetrist

Telephone: _____ Fax: _____ E-mail: _____

Signature of Person Completing This Benchmark: _____

1. Planning system/software used for image fusion/registration: _____

a. Version no: _____

2. Available registration methods:

_____ Match points
_____ Automatic registration
_____ Manual translation and rotation
_____ Other, please specify _____

3. Registration method used for this benchmark: _____

4. Available methods used for visualizing the registration:

_____ Checkerboard/split images
_____ Overlaid images
_____ Other, please specify _____

5. For this benchmark please list the x, y, z coordinates in the CT coordinate system of the following two points:

Center of target volume _____, _____, _____

Center of 1st rod on most inferior CT slice _____, _____, _____

Please save and submit with supporting documents to QARC via sFTP.

Or